

10. Animal Tissue



Can you recall?

1. What is tissue?
2. Where is squamous epithelial tissue located?
3. Enlist functions of bone.



Do you know ?

Number of cells in human body.

As we know tissue is a group of cells having same embryonic origin, structure and function. Various tissues combine together in an orderly manner to form large functional unit called organs. These organs combine together and form organ-system. The cells are of two types, somatic cells and germ cells. The word somatic is derived from the Greek word 'soma' means 'body'. All body cells of an organism except sperm and ova are somatic cells. The sperm and ova are germ cells. They belong to reproductive system.

Cells → Tissues → Organs → Organ systems → Body

10.1 Histology : The study of the structure and arrangement of tissue is called histology. There are four types of tissues present in animals namely epithelial, connective, muscular and nervous. Let us study each type in details.



Know the scientist

Marie Francois Xavier Bichat (1771-1802), French anatomist and pathologist discovered tissue. He was known as 'Father of Histology'.



Marie Francois Xavier

10.2 Epithelial tissue (epi : above, thelium : layer of cells)

Epithelial tissue forms a covering on inner and outer surface of body and organs.

The cells of this tissue are compactly arranged with little intercellular matrix. Cells rest on non-cellular basement membrane.

Cells are polygonal, cuboidal or columnar in shape. Single nucleus is present at the centre or at the base. This tissue is avascular. It has good capacity of regeneration. Major function is protection and it also helps in absorption, transport, filtration and secretion. Epithelial tissue is classified into two types : Simple epithelium and Compound epithelium. Simple epithelium is made up of single layer of cells. Compound epithelium is made up of two or more layers of cells. Lowermost layer lies on basement membrane.

A. Simple epithelium :

1. Squamous epithelial tissue : Cells of this tissue are flat, thin, polygonal with serrated margin. Cells of this tissue fit together like tiles of footpath. Hence it is called pavement epithelium. Prominent spherical or oval nucleus is present at the centre of the cell. Function : Protection, absorption, transport, filtration, secretion. It is found in blood vessels, alveoli, coelom, etc.

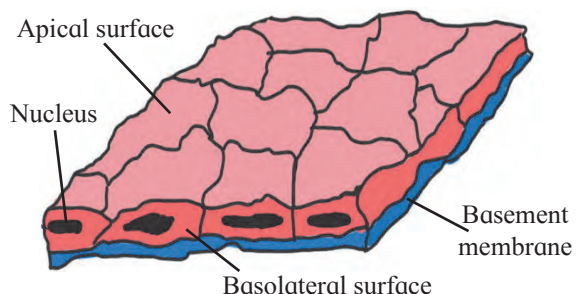


Fig. 10.1 Squamous epithelial tissue

2. Cuboidal epithelium : In this, the cells are cuboidal in shape with a spherical nucleus at the centre. Function : Absorption, secretion. It is found in lining of pancreatic duct, salivary duct, proximal and distal convoluted tubules of nephron.

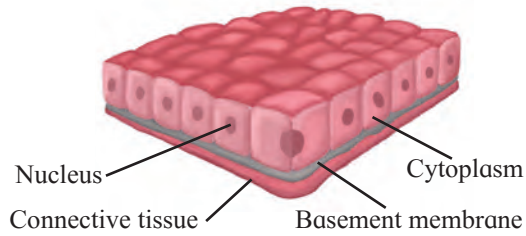


Fig. 10.2 Cuboidal epithelium

3. Columnar epithelium : Columnar epithelial cells are tall, pillar like. Inner ends of the cells are narrow while free ends are broad and flat. Free surface shows large number of microvilli. Nucleus is oval and is present in the lower half of the cell. Function : Secretion, absorption. It is found in inner lining of intestine, gall bladder, gastric glands, intestinal glands, etc.

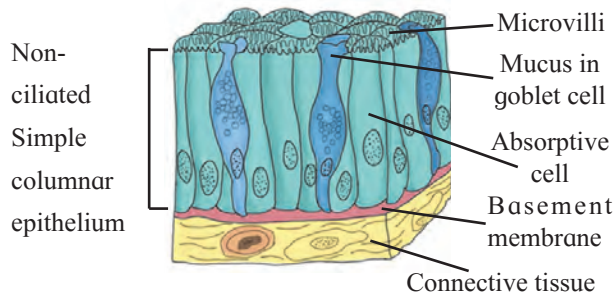


Fig. 10.3 Columnar epithelium

4. Ciliated epithelium : Cells of this tissue are cuboidal or columnar. Free ends of cells are broad while narrow ends rest on a basement membrane. Free ends show hair like cilia. Nucleus is oval and placed at basal end of cell. Function : To create a movement of materials in contact in a specific direction and thus able to prevent entry of foreign particles in the trachea, push the ovum through oviduct. It is found in inner lining of buccal cavity of frog, nasal cavity, trachea, oviduct of vertebrates, etc.

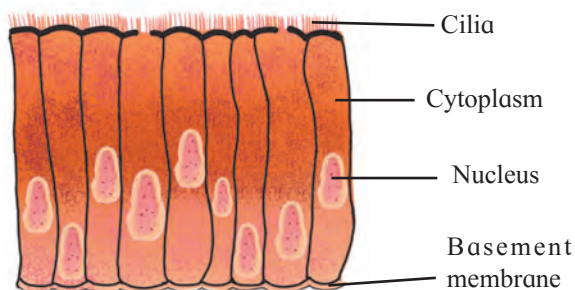


Fig. 10.4 Ciliated epithelium

5. Glandular epithelium : Here, the cells may be columnar, cuboidal or pyramidal in shape. Nucleus is large and situated towards the base. Secretory granules are present in the cytoplasm.

The glands may be unicellular (goblet cells of intestine) or multicellular (salivary gland) depending on the number of cells. Depending on mode of secretion, multicellular glands can be classified as duct bearing glands (exocrine glands) and ductless glands (endocrine glands).

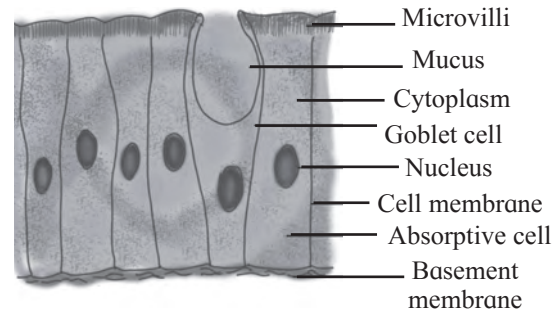


Fig. 10.5 Glandular epithelium

Exocrine glands pour their secretions at a specific sites e.g. Salivary gland, sweat glands etc. Endocrine glands release their secretions directly into blood stream. e.g. thyroid gland, pituitary gland, etc. Function : Secrete the mucus that trap the dust particles, lubricates the inner surface of respiratory and digestive tracts, secretion of enzymes and hormones.

6. Sensory epithelial tissue : It is composed of modified form of columnar cells and elongated neurosensory cells. Sensory hairs are present at the free end of the cell. Function : It perceive external as well as internal stimuli. These are found in nose (Olfactory) Ear (Auditory hair cells) Eye (Photoreceptors).

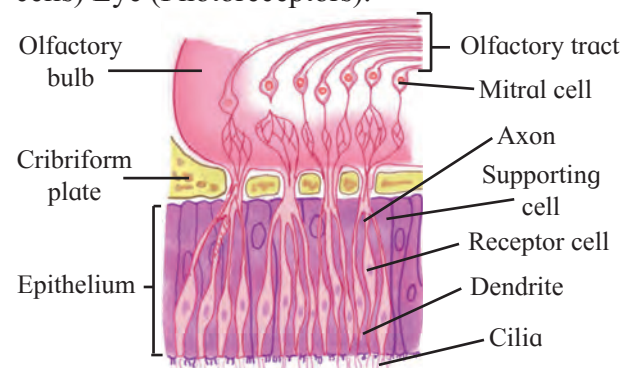
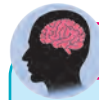

Fig. 10.6 Sensory epithelium

7. Germinal epithelium : Cells of this epithelium divide meiotically to produce haploid gametes. Ex. : Lining of seminiferous tubules, inner lining of ovary.



Use your brain power

When do the transitional cells change their shape ?

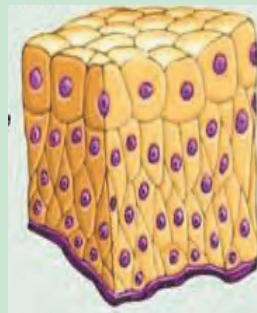
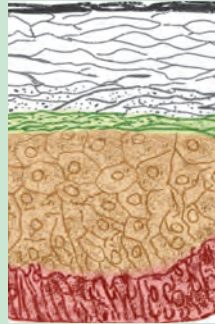
B. Compound epithelium :

a. Stratified epithelium :

Nucleus is present in stratum germinativum. Cells at free surface become flat and lack nucleus called stratum corneum.

Function : Protection

Ex. : Epidermis of skin, oesophagus cornea, vagina, rectum.



b. Transitional epithelium:

Structure of transitional epithelium is same like stratified epithelium. The cells can undergo a change in their shape and structure depending on degree of stretch.

Function : Distension of organ

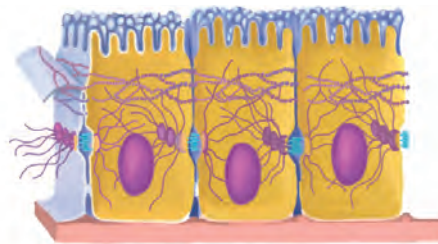
Ex. : Urinary bladder

Fig. 10.7 Compound epithelial tissues

Cell junctions : The epithelial cells are connected to each other laterally as well as to the basement membrane by junctional complexes called cell junctions.

Tight junctions (TJs):

These junctions maintain cell polarity, prevent lateral diffusion of proteins and ions.

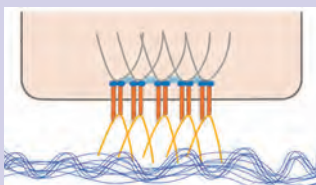


Gap Junctions (GJs) :

This intercellular connection allows passage of ions and small molecules between cells as well as exchange of chemical messages between cells.

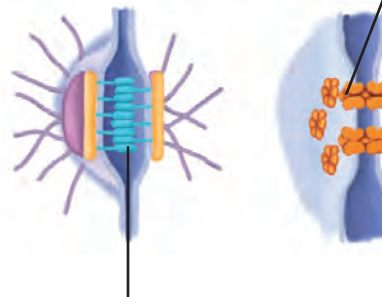
Hemidesmosomes (HDs) :

Allow the cells to strongly adhere to the underlying basement membrane. These maintain tissue homeostasis by signaling.



Desmosomes (Ds) :

These provide mechanical strength to epithelial tissue, cardiac muscles and meninges.



Adherens Junctions (AJs) :

It is involved in various signaling pathways and transcriptional regulations.

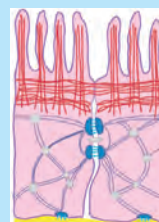


Chart 10.8 Types of Cell junction :



Can you tell?

1. Explain basic structure of epithelial tissue and mention its types.
2. Epithelial tissue has good capacity of regeneration. Give reason.
3. Write a note on glandular epithelial tissue.
4. How do cell junctions help in functioning of epithelial tissue?

10.3 Connective tissue : It is most widely spread tissue in the body. It binds, supports and provides strength to other body tissues and organs. It consists of a variety of cells and fibres. These are embedded in the abundant intercellular substance called matrix. Connective tissue protects the vital organs of the body. It is highly vascular except cartilage. It acts as packing material and also helps in healing process.

Connective tissue is classified on the basis of matrix present, as connective tissue proper, supporting connective tissue and fluid connective tissue. Connective tissue proper is further classified as loose connective tissue (ex. areolar connective tissue and adipose tissue) and dense connective tissue (ex. ligament and tendon). Supporting connective tissue also called skeletal tissue includes cartilage and bone. Fluid connective tissue includes blood and lymph.

A. Connective Tissue Proper

Loose connective tissue : Matrix of loose connective tissue is semisolid, jelly like, viscous matter made up of gelatin.

1. Areolar tissue (Areola : air pockets):

Matrix of this tissue contains two types of fibres namely white fibres and yellow fibres. White fibres are made up of collagen. They give tensile strength to the tissue. Yellow fibres are made up of elastin and are elastic in nature. The tissue also contains four different types of cells; fibroblast the large flat cells having branching processes.

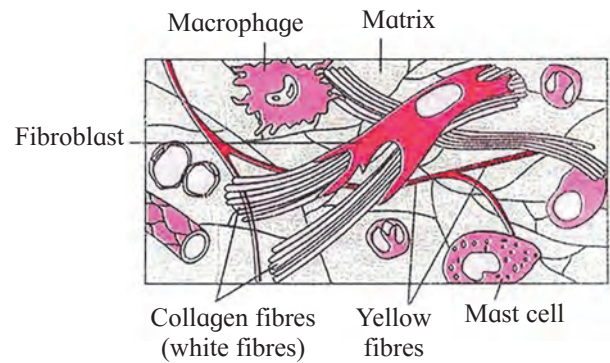


Fig. 10.9 Areolar tissue

They produce fibres as well as polysaccharides that form the ground substance or matrix of the tissue. Mast cells are oval cells that secrete heparin and histamine. Macrophages are amoeboid, phagocytic cells. Fat cells, also called adipocytes have eccentric nucleus. These cells store fat. This tissue acts as packing material, helps in healing process and connects different organs or layers of tissues. It is found under the skin, between muscles, bones, around organs, blood vessels and peritoneum.

2. Adipose tissue (Adipo : fat) : In this tissue large number of adipocytes are present. Cells are rounded or polygonal. Nucleus is shifted to periphery because fats are stored in the cell in the form of droplets. Matrix is less and fibres and blood vessels are few in number.

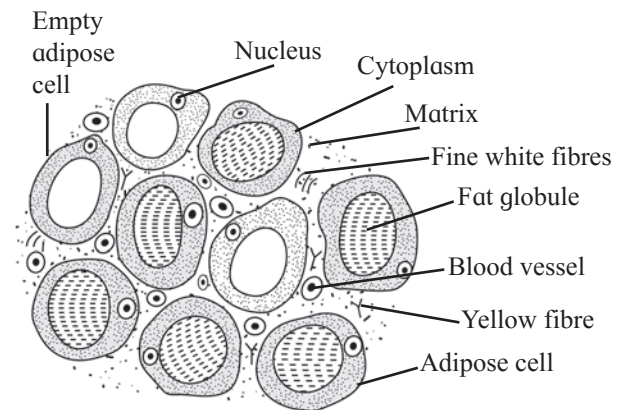


Fig. 10.10 Adipose tissue

There are two types of adipose tissue : white adipose tissue appears opaque due to presence of large number of adipocytes. It is commonly seen in adults. Brown adipose tissue is reddish brown in colour due to presence of large number of blood vessels.

Function : Adipose tissue is a good insulator, acts as a shock absorber and a good source of energy because it stores fat. The tissue is found in sole and palm region as well as around organs like kidney.



Know your body

Achilles Tendon : Achilles Tendon connects the calf muscles to heel bone. Pain at the back of ankle or lower calf may signal a problem with an Achilles Tendon. Athletes who participate in track and field may face Achilles tendon injury. Most tendon injuries occur near joints such as the shoulder, elbow, knee and ankle.

B. Dense Connective Tissue

In this tissue, fibres and fibroblasts are compactly arranged. There are two types, namely dense regular and dense irregular tissue.

In dense regular connective tissue, collagen fibres are arranged in parallel manner. Two major examples of this tissue are tendons and ligaments. Tendons connect skeletal muscles to bones. To give tensile strength to the tissue, tendons contain bundles of white fibres. E.g. Achilles tendon, Hamstring tendon.

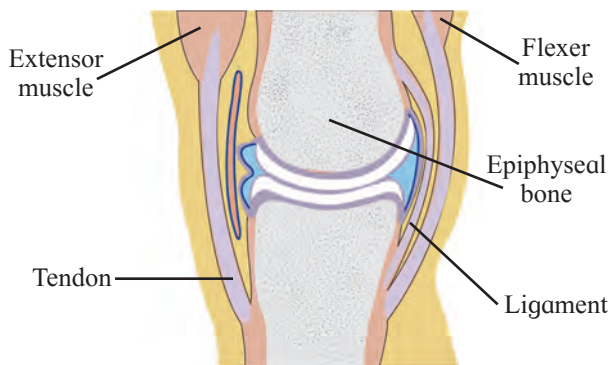


Fig. 10.11 Ligament

Ligaments are made up of elastic or yellow fibres arranged in regular pattern. These fibres make ligaments elastic. They are present at joints. They prevent dislocation of bones.

In dense irregular connective tissue fibres and fibroblast are not arranged in orderly manner. This tissue is found in dermis of skin.

C. Supporting Connective Tissue

It is characterized by presence of hard matrix. It is classified into two types cartilage and bone.

Cartilage : This is a pliable yet tough tissue. It forms endoskeleton of cartilaginous fishes like shark. It is widely distributed in vertebrate animals. In cartilage, abundant matrix is delimited by a sheath of collagenous fibres called perichondrium. Matrix is called chondrin. Just below the perichondrium, immature cartilage forming cells called chondroblast are present. Chondroblasts mature and get converted into chondrocytes. Chondrocytes are seen scattered in the matrix. They are enclosed in lacunae. Each lacuna contains 2-8 chondrocytes.

Based upon the type of matrix, there are four types of cartilage as explained below.

Hyaline cartilage (Hyaline : Glass like) : In this type of cartilage, perichondrium is present. Matrix is bluish white and gel like.

Very fine collagen fibres and chondrocytes are present. Hyaline cartilage is elastic and compressible in nature. It acts as a good shock absorber as well as provide flexibility. It reduces friction. It is found at the ends of long bones, epiglottis, trachea, ribs, larynx and hyoid.

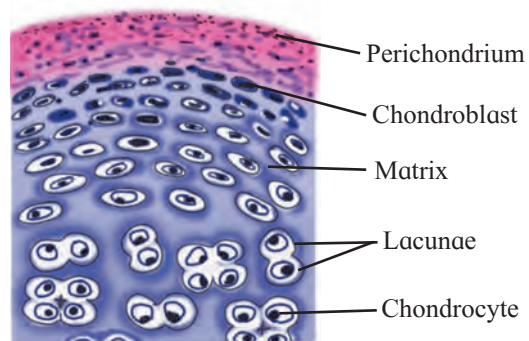


Fig. 10.12 Hyaline Cartilage

Elastic cartilage : In elastic cartilage perichondrium is present. Matrix contain elastic fibres. Chondrocytes are few in number. It gives support and maintains shape of the body part. It is found in ear lobe, tip of nose, etc.

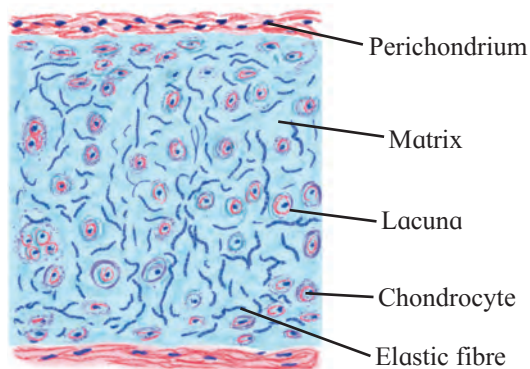


Fig. 10.13 Elastic cartilage

Fibrocartilage : Perichondrium is absent in fibrocartilage. Matrix contains bundles of collagen fibres and few chondrocytes, scattered in fibres. Fibrocartilage is most rigid cartilage. It maintains position of vertebrae. Intervertebral discs are made up of fibrocartilage. It is also found at pubic symphysis.

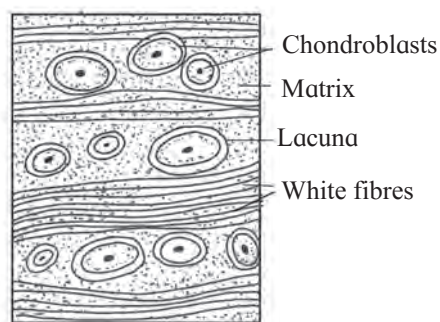


Fig. 10.14 White fibrous cartilage

Calcified cartilage : This type of cartilage becomes rigid due to deposition of salts in the matrix. This reduces flexibility of joints in old age e.g. Head of long bones.

Bone : Bone is characterised by hard matrix called Ossein. Ossein is made up of mineral salt hydroxy-apatite ($\text{Ca}_{10}(\text{PO}_4)_6(\text{OH})_2$). Outer tough membrane called periosteum encloses the matrix. Blood vessels and nerves pierce through periosteum. Matrix is arranged in the form of concentric layers called lamellae.

Each lamella contains fluid filled cavities called lacunae. Fine canals that radiate from each lacuna are called canaliculi. Canaliculi of adjacent lamellae connect with each other as they traverse through the matrix. In the lacunae osteoblasts, active bone cells and osteocytes, the inactive bone cells and osteoclasts are present. Mammalian bone shows peculiar haversian system. Haversian canal encloses an artery, vein and nerves. Observe figure 10.15 to understand haversian system. According to presence of matrix there are two types of bones present in human body. In **spongy** bones, haversian system is absent. Reticular matrix is arranged in the form of trabeculae. It contains red bone marrow. In **compact** bones, matrix shows haversian system without any space between lamellae.

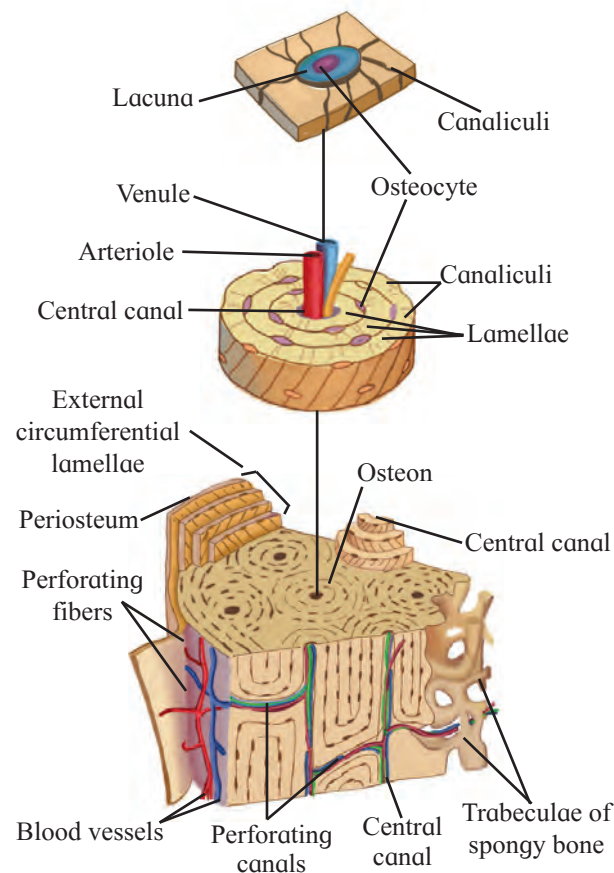


Fig. 10.15 Bone detailed structure



Can you tell?

1. Give reason.
 - a. Bone is stronger than cartilage.
 - b. As we grow old, cartilage becomes rigid.
2. Explain histological structure of mammalian bone.

D. Fluid Connective tissue (Vascular)

Blood and lymph are fluid connective tissue present in the body of an animal. You will study these tissues in details in chapter 'Circulation' in class XII.



Can you recall?

1. How many skeletal muscles are present in human body ?
2. How can exercise improve your muscular system ?

10.4 Muscular tissue :

The cells of this tissue are elongated and are called muscle fibres. Each muscle fibre is covered by a membrane sarcolemma. Cytoplasm of muscle cell is called sarcoplasm. Large number of contractile fibrils called myofibrils are present in sarcoplasm. One or many nuclei are present in muscle cell depending on the type. Myofibrils are made up of proteins, actin and myosin. Muscle fibres contract and decrease in length on stimulation. Hence, muscular tissue is known as contractile tissue. It is vascular tissue and is innervated by nerves too. Muscle cells contain large number of mitochondria.

A. Types of Muscular Tissue

1. Skeletal muscles : These muscles are found attached to bones. Skeletal muscles consists of large number of fasciculi which are wrapped by connective tissue sheath called epimysium or fascia. Each individual fasciculus is covered by perimysium. Each fasciculus in turn consists of many muscle fibres called myofibres.

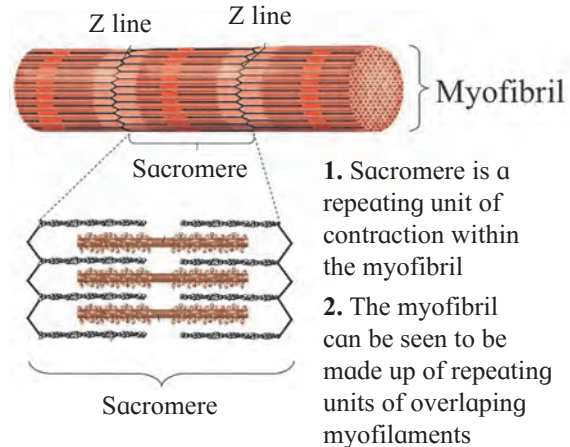
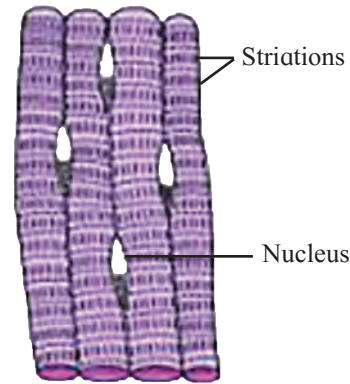


Fig. 10.16 Muscular tissue

Each muscle fibre is a syncytial fibre that contains several nuclei. The cell membrane called sarcolemma delimits the cytoplasm called sarcoplasm. Sarcoplasm contains large number of parallelly arranged myofibrils hence nuclei get shifted to periphery. Each myofibril is made up of repeated functional units called sarcomeres. Each sarcomere has a dark band called anisotropic or 'A' band in the centre. In the centre of 'A' band is light area called 'H' zone or 'Hensen's Zone'. In the centre of 'H' zone there is 'M' line. 'A' bands are made up of myosin as well as actin. On either side of 'A' band are light bands called isotropic or 'I' bands that contain only actin. Myosin are thick and dark coloured while actin filaments are thin and light coloured. Adjacent light bands are separated by 'Z' line (Z - Zwischenscheibe line). Dark and light bands on neighbouring myofibrils correspond with each other hence the muscle gets striated appearance.

Skeletal muscles show quick and strong voluntary contractions. They bring about voluntary movements of the body. You will study about working of skeletal muscles in the chapter movement and locomotion.

Red and white muscles : On the basis of amount of a red pigment, skeletal muscles are of two main types – Red and white. Red muscles contain very high amount of myoglobin while white muscles contain very low amount of this pigment.

Myoglobin is an iron containing red coloured pigment only in muscles. It consists of one haeme and one polypeptide chain. It can carry one molecule of oxygen. Due to presence of myoglobin, the muscles can obtain their oxygen from two sources, myoglobin and haemoglobin.

2. Smooth or Non-striated muscles :

These muscles are present in the form of sheets or layers. Each muscle cell is spindle shaped or fusiform. The fibres are unbranched having single nucleus at the centre. Sarcoplasm contains myofibrils. Myofibrils are made up of contractile proteins actin and myosin. Smooth muscles contain less myosin and more actin as compared to skeletal muscles. Striations are absent. These muscles undergo slow and sustained involuntary contractions. They are innervated by autonomous nervous system.

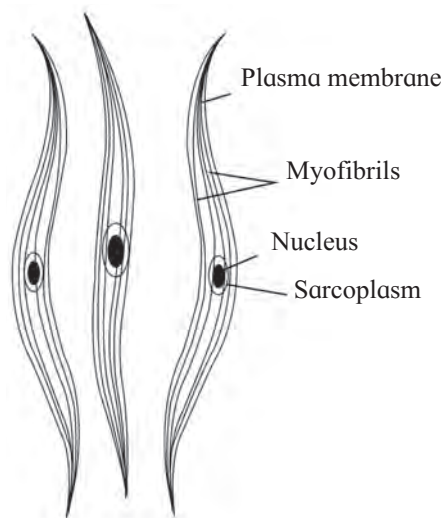


Fig. 10.17 Smooth muscle

These are found in the walls of visceral organs and blood vessels. Hence they are also called as visceral muscles. They may be arranged lengthwise (longitudinal muscles) or around circumference (circular muscles) of any organ.

3. Cardiac Muscles : Muscles of this tissue show characters of both striated and non-striated fibres. Sarcolemma is not distinct. Hence uni-nucleate muscle fibres appear to be multi-nucleate. Adjacent muscle fibres join together to give branched appearance to the tissue. Points of adhesion of muscle fibres are formed by transverse thickenings of sarcolemma called intercalated discs.

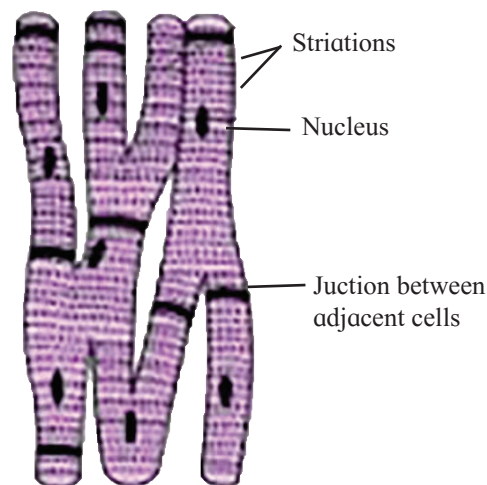


Fig. 10.18 Cardiac muscles

These junctions at places allow cardiac muscles to contract as a unit. i.e. It helps in quick transfer of stimulus. The cardiac muscles are striated involuntary muscles.

Some mammalian cardiac muscles are modified and are capable of generating impulse on their own. Hence mammalian heart is a myogenic heart. In some animals, cardiac muscles need neural stimulus to initiate the contraction. Such a heart is called neurogenic heart. Cardiac muscles form myocardium of the heart wall.



Can you tell?

Compare and contrast between various types of muscles.

B. Nervous Tissue :

Nervous tissue is composed of nerve cells or neurons and neuroglia. Neuron is the structural and functional unit of nervous system. Neuroglial cells are non-nervous supporting cells that fill in the interneuronal space. The neuroglial cells are capable of regeneration and division but neurons are not capable of regeneration because of lack of centriole. Intercellular matrix is absent in the neural tissue. Neuron is an impulse generating and impulse conducting unit. They bring about quick communication within the body. Neurons change action potential of their membrane on receiving any external stimulus. This property of neuron is called excitability. They also carry a wave of electric impulse from dendron to axon, the processes of neuron. This is called conductivity.

A **neuron** is made up of cyton or cell body. It contains granular cytoplasm called neuroplasm and centrally placed nucleus. Neuroplasm contains mitochondria, Golgi apparatus, RER and granules called Nissl's granules. They are made up of RNA. Cell body gives out two types of processes namely dendron and axon. Dendrons are short, branched, processes. The fine branches of dendron are called dendrites. They carry impulse towards cyton.

An axon is single, elongated, cylindrical process. Axon is bounded by axolemma. The protoplasm of the axon is axoplasm. It contains large number of mitochondria and neurofibrils. Axon is enclosed in a fatty sheath called myelin sheath. Outer covering of myelin sheath is neurilemma. Myelin sheath and neurilemma are parts of another cell called Schwann's cell. Schwann cell shows nucleus at periphery. The myelin sheath is absent at intervals along the axon and the place is called Node of Ranvier. The terminal arborization of an axon is called telodendron.

Based on their functions, Neurons are classified into three types

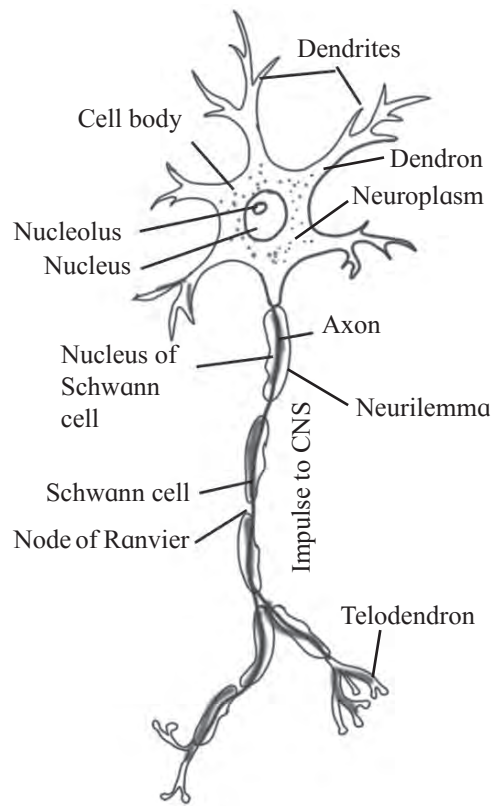


Fig. 10.19 Structure of Multipolar Neuron

Afferent Neuron : It carries impulses from sense organ to central nervous system (CNS). Hence it is also called sensory neuron. It is found in dorsal root of spinal cord.

Efferent Neuron : It carries impulses from CNS to effector organ. Hence it is also called motor neuron. It is found in ventral root of spinal cord.

Interneuron or association neuron : These are located between sensory and motor neurons. These perform processing, integration of sensory impulses and activate appropriate motor neuron to generate motor impulse.

Depending on the presence or absence of myelin sheath, neurons are classified into two types. i.e. myelinated and non-myelinated nerve fibre.

Myelinated or medullated nerve fibres have a insulating fatty layer called myelin sheath around the axon. This makes the fibre appear white in colour. This sheath is secreted by Schwann cells. The sheath is not continuous. It is interrupted at nodes of Ranvier. Neurilemma surrounds the axon.

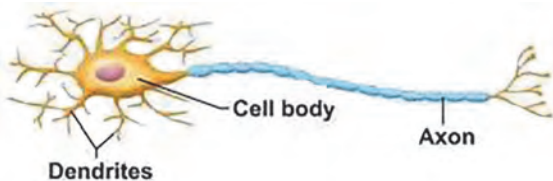
The impulse is conducted at a faster rate in such nerve fibres because it jumps from one node to the next. Such transmission of impulse is called saltatory conduction. Myelin sheath prevents the loss of the impulse during conduction. Cranial nerves of vertebrates are myelinated. Schwann cell of a non-medullated nerve fibre does not secrete myelin sheath. These fibres are grey in colour due to absence of fatty layer. Conduction of impulse in a non-myelinated fibre is slower as compared to myelinated nerve fibre. Nerves of autonomous nervous system are non-myelinated. Functional contact between axonal ends and dendrites of adjacent neurons is called a synapse. You will learn about synapse in chapter control and coordination, class-XII.

- 1. Unipolar/Monopolar Neuron :** It has a single process originating from cyton. Both axon and dendron arise from cyton at one point. They conduct impulses to central nervous system. Ex. Neurons of dorsal root ganglion of spinal nerve.
- 2. Bipolar Neuron :** It has two processes. A single dendron and an axon are given off from opposite poles of the cyton. They bring about transmission of special senses like sight, smell, taste, hearing etc. Ex. Neurons of retina of eye, olfactory epithelium.
- 3. Multipolar Neuron :** Cyton is star shaped and gives out more than two processes. There is only one axon and remaining are dendrons. Axon initiates from a funnel shaped area called axon-hillock.



Internet my friend

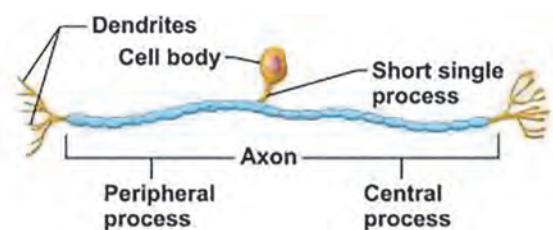
Learn about transmission of impulse from one neuron to another.



a. Multipolar neuron



b. Bipolar neuron



c. Unipolar neuron

Fig. 10.19 Nervous tissue

Based on the number of processes given out from cyton, neurons are classified into three types.



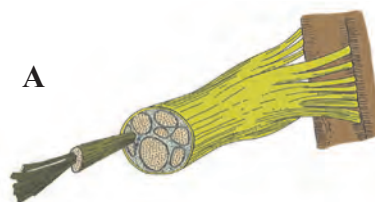
Can you tell?

1. Differentiate between medullated and non medullated fibre.
2. Classify neuron on the basis of number of processes given out from cyton with examples.

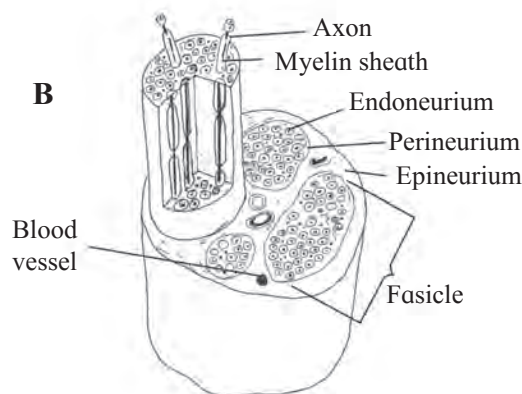


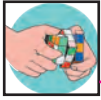Observe and Discuss

Explain the structure of nerve.



Covering of a spinal nerve





Exercise

1. Choose correct option

- A. The study of structure and arrangement of tissue is called as _____
 a. anatomy b. histology
 c. microbiology d. morphology
- B. _____ is a gland which is both exocrine and endocrine.
 a. Sebaceous b. Mammary
 c. Pancreas d. Pituitary
- C. _____ cell junction is mediated by integrin.
 a. Gap b. Hemidesmosomes
 c. Desmosomes d. Adherens
- D. The protein found in cartilage is _____.
 a. ossein b. haemoglobin
 c. chondrin d. renin
- E. Find the odd one out
 a. Thyroid gland b. Pituitary gland
 c. Adrenal gland d. Salivary gland

2. Answer the following questions:

- A. Identify and name the type of tissues in the following:
 a. Inner lining of the intestine
 b. Heart wall
 c. Skin
 d. Nerve cord
 e. Inner lining of the buccal cavity
- B. Why do animals in cold regions have a layer of fat below their skin?
- C. What enables the ear pinna to be folded and twisted while the nose tip can't be twisted?
- D. Sharad touched a hot plate by mistake and took away his hand quickly. Can you recognize the tissue and its type responsible for it?
- E. Priya got injured in an accident and hurt her long bone and later on she was also diagnosed with anaemia. What could be the probable reason?

- F. Supriya stepped out into the bright street from a cinema theatre. In response, her eye pupil shrunk. Identify the muscle responsible for the same.

3. Answer the following questions

- A. What is cell junction? Describe different types of cell junctions.
- B. With help of neat labelled diagram, describe the structure of areolar connective tissue.
- C. Describe the structure of multipolar neuron.
- D. Distinguish between smooth muscles and skeletal muscles.

4. Complete the following table

	Cell / Tissue / Muscles	Functions
1.	Cardiac muscles	-----
2.	-----	Connect skeletal muscles to bones.
3.	Chondroblast cells	-----
4.	-----	Secrete heparin and histamine

5. Match the following and rewrite:

'A' Group

- Muscle
- Bone
- Nerve cell
- Cartilage

'B' Group

- Perichondrium
- Sarcolemma
- Periosteum
- Neurilemma

Practical / Project :

- To study the different tissues with the help of permanent slides in your college laboratory.
- Collect the information about the exercise to keep muscles healthy and strong.